Poster number

605

Immediate Insertion of 5.4 mm OsseoSpeed™ EV Implants into Molar Extraction Sites

R.Noelken[1,2], F.Oberhansl[1], M.Moergel[2], W. Wagner[2]

[1]Private Practice for Oral Surgery, Lindau/Lake Constance, Germany

[2]Department of Oral and Maxillofacial Surgery - Plastic Surgery, University Medical Center, Johannes Gutenberg University of Mainz, Germany

Topic: Implant insertion after tooth extraction: Clinical outcomes with different approaches

BACKGROUND AND AIM

To overcome the disadvantages of staged implant surgery, immediate insertion concepts as well as flapless surgery approaches have been introduced in recent years. However, there are just a few studies that illustrate results of immediate insertion of implants into fresh extraction sockets of molars. With the introduction of ASTRA TECH Implant System™ EV, a dental implant with a wider implant diameter, OsseoSpeed™ EV 5.4S (DENTSPLY Implants, Mölndal, Sweden), has been developed to improve primary stability even in larger extraction sites. This pilot study examined the clinical performance of OsseoSpeed™ EV 5.4S implants in a one-stage procedure with immediate insertion and peri-implant grafting in molar extraction sites with a follow-up period of up to 2.5 years.

METHODS AND MATERIALS

41 implants were inserted in 35 patients. All implants were placed immediately into the center of molar extraction sockets. Peri-implant bony defects resulting from the extraction of the multi-rooted teeth were reconstructed simultaneously with autogenous bone chips in a flapless approach. All implants received wide healing abutments (HealDesign™ EV 6.5 mm diameter) for a one-stage treatment protocol. The primary outcome variables were marginal bone level change, and the secondary outcome variables were implant survival and soft tissue parameters.

Fig.1: Astra Tech OsseoSpeed™ EV implant with diameter 5.4 mm.

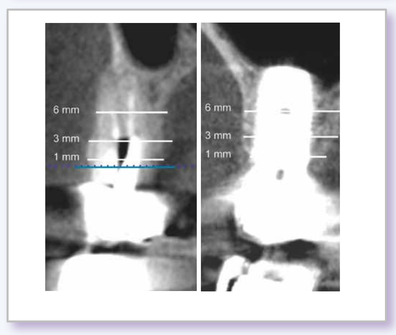

Fig.2: Measurement technique of the total width of the crest 1, 3 and 6 mm below reference level.

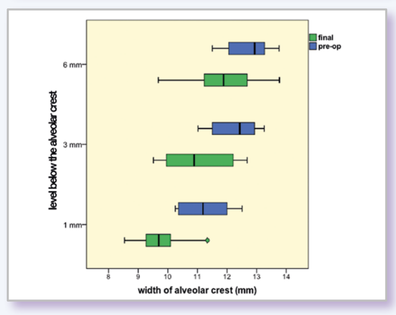

Fig.3: The horizontal width of the alveolar crest was significantly reduced at a level 1 mm below the crest from 11.3 to 9.9 mm (12.4%), at 3 mm from 12.2 to 11.1 mm (9%) and at 6 mm from 12.7 to 11.9 mm (6.3%).

RESULTS

Mean insertion torque at the time of implant insertion was 29 Ncm. Two additional implants had to be removed at implant insertion and excluded from the study because of insufficient primary stability. Mean follow-up was 14 months (range, 4 to 30 months). There was no implant loss (cumulative survival rate 100%). The vertical marginal bone level was successful reconstructed up to the level of the implant shoulder from the time of implant insertion to the final follow-up. However, the horizontal width of the alveolar crest was significantly reduced at a level 1 mm below the crest from 11.3 to 9.9 mm (12.4%), at 3 mm from 12.2 to 11.1 mm (9%) and at 6 mm from 12.7 to 11.9 mm (6.3%). The width of the keratinized mucosa remained stable; peri-implant probing depth ranged between 2 and 5 mm.

CONCLUSIONS

Stability of vertical marginal bone levels, limited horizontal crestal resorption, high cumulative survival rate and soft tissue stability indicate proof of principle for immediate insertion of OsseoSpeed™ EV 5.4S implants in molar extraction sites.

Fig.4a: Pre-op aspect of hopeless molars in the left maxilla.

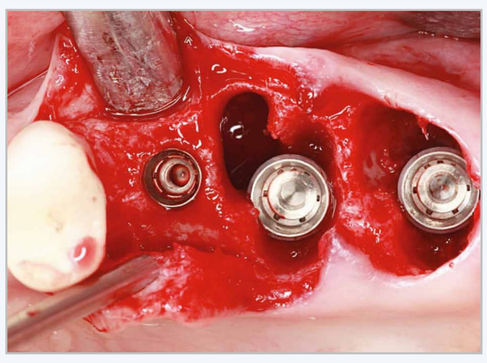

Fig.4b: Immediate implant insertion in molar extraction sites.

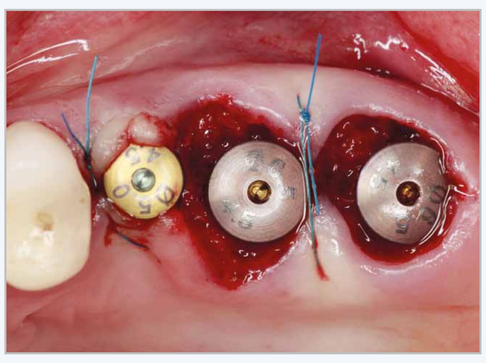

Fig.4c: Peri-implant defects were grafted with autogenous bone chips from the mandibular ramus.

Fig.4d: At 2 weeks the graft is covered completely by granulation tissue.

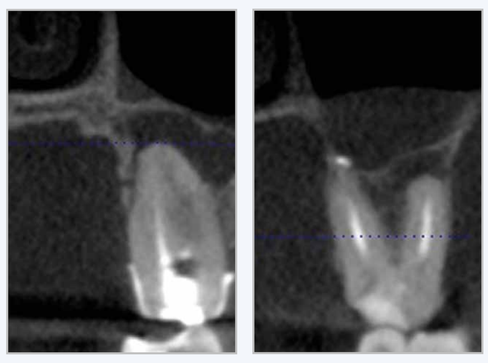

Fig.4e & f: Pre-op CB-CT of hopeless teeth 26 and 27 with large apical lesions.

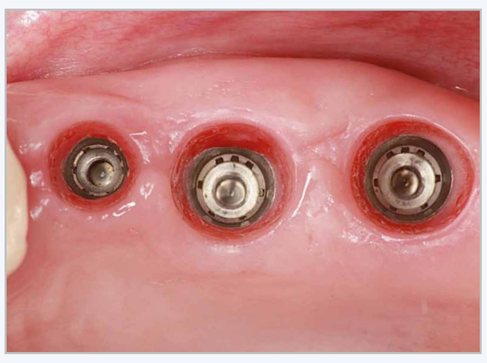

Fig.4g: Excellent soft tissue healing around the OsseoSpeed EV 5.4S implants.

Fig.4h: Delivery of Atlantis zirconia abutments at 3 months.

Fig.4i: Stable buccal bone and soft tissue contour at 1 year.

Fig.4j: Maintained buccal soft tissue level 1 year following immediate insertion in molar extraction site.

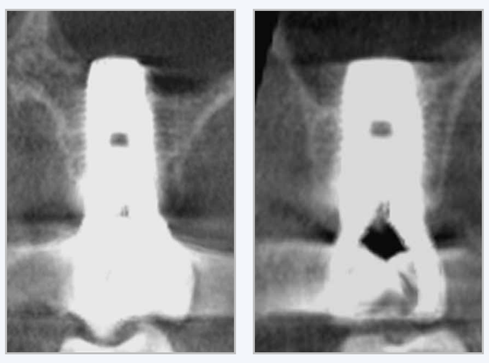

Fig.4k & l: CB-CT at 1 year of implants 26 and 27 shows maintenance of crestal width.

Fig.5a: Initial clinical situation showing fistula of tooth 46 caused by strip perforation.

Fig.5b: Pre-op occlusal view is showing buccal swelling and fistula.

Fig.5c: Clinical situation 2 months after immediate implant placement into molar extraction site.

Fig.5d: Occlusal view at 2 month showing maintained bone volume.

Fig.5e: Pre-op x-ray of fractured tooth.

Fig.5f: CB-CT at insertion with autogenous bone grafting.

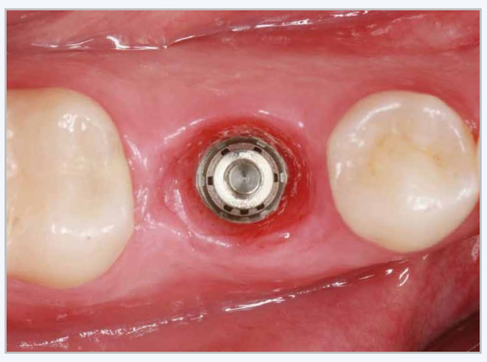

Fig.5g: Occlusal view of the implant shoulder at prosthesis delivery at 3 month.

Fig.5h: Delivery of ATLANTIS titanium abutment with natural support of the emergence profile at 3 month.

Fig.5i: Occlusal view of implant crown at 18 months shows only minimal horizontal bone resorption.

Fig.5j: Maintenance of natural marginal soft tissue contour at the implant crown at 18 month.

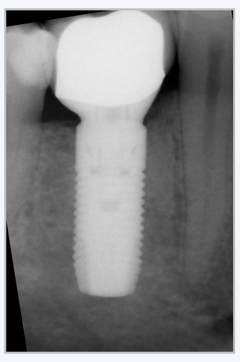

Fig.5k: Maintained marginal bone levels at 18 month.

Fig.5l: Minimal horizontal bone resorption at 18 month.

REFERENCES

Hamouda NI et al. Immediate implant placement into fresh extraction socket in the mandibular molar sites: a preliminary study of a modified insertion technique. Clin Implant Dent Relat Res. 2015; 17 Suppl 1:e107-16.

Rebele SF et al. Pre-extractive interradicular implant bed preparation: case presentations of a novel approach to immediate implant placement at multirooted molar sites. Int J Periodontics Res Dent 2013; 33: 89-96.

Schropp L et al. Bone healing and soft tissue contour changes following single-tooth extraction: a clinical and radiographic 12-month prospective study. Int J Perio Restorative Dent 2003; 23: 313-323.

CONTACT

Robert Noelken, Priv-Doz Dr Med Dent MSc

Augustusplatz 2, D-55131 Mainz (clinic) & Paradiesplatz 7-13, D-88131 Lindau (practice)

E-mail: rnoelken@me.com

Presented at

EAO CONGRESS STOCKHOLM SEPTEMBER 24-26.2015 EAO-CONGRESS.COM CHALLENGES IN IMPLANT TREATMENT